

Stephan Vehmeijer



orthooped sinds 2004

voorstes benadering sinds 2006

Rapid Recovery sinds 2009

dagbehandeling THP sinds 2014

Rapid Recovery



dagbehandeling THP  
(bij overigens gezonde patiënten)

doel van Rapid Recovery



**niet** om patiënten op de dag van de operatie naar huis te *sturen*

doel van Rapid Recovery



om patiënten beter te laten herstellen  
om patiënten zich beter te laten voelen

## doel van Rapid Recovery



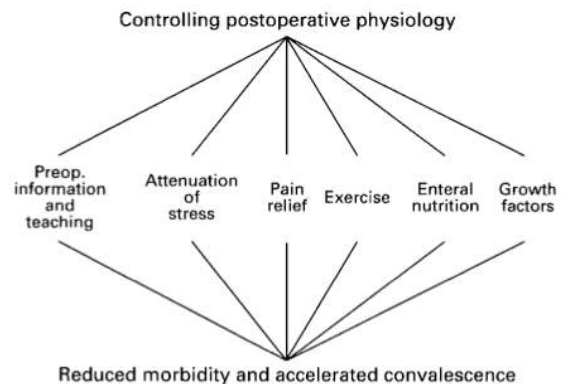
om patiënten naar huis te *laten gaan* als het kan

## Henrik Kehlet



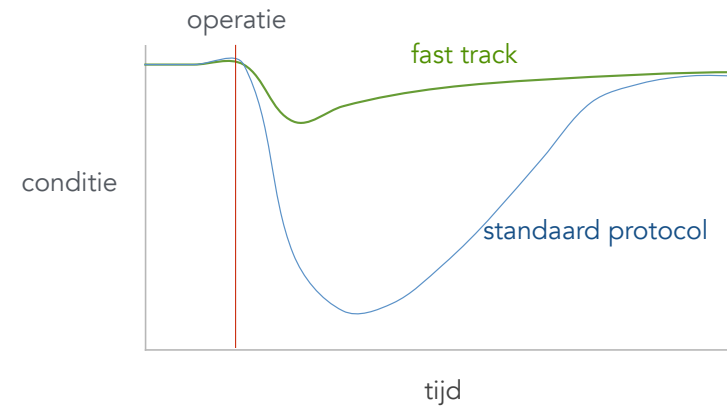
heel veel onderzoek naar Rapid Recovery

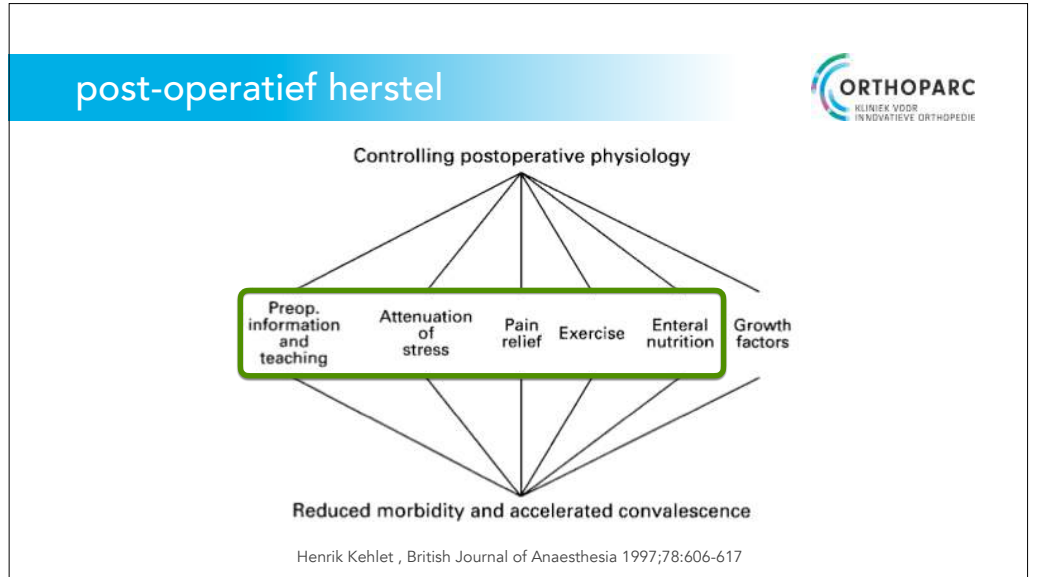
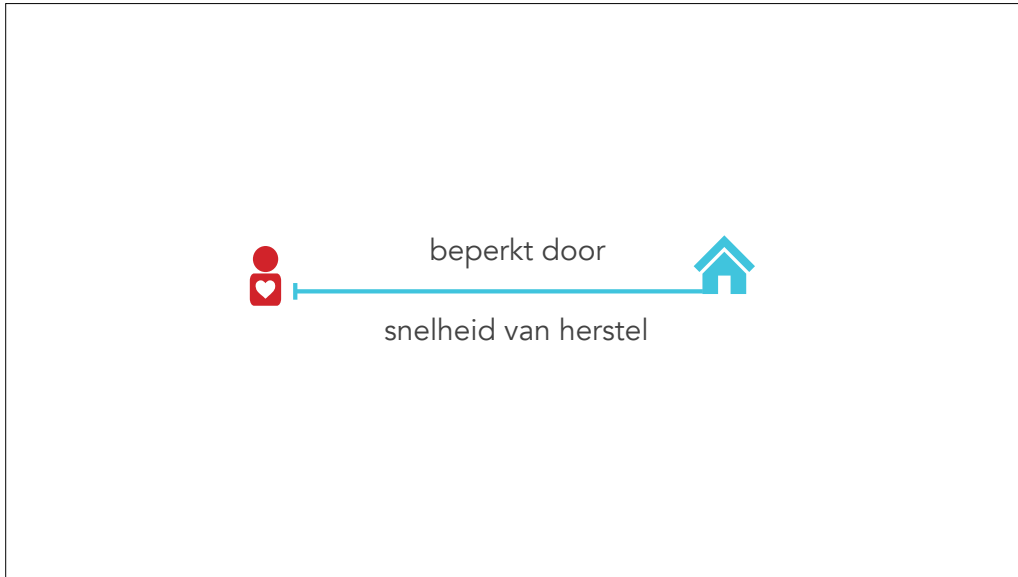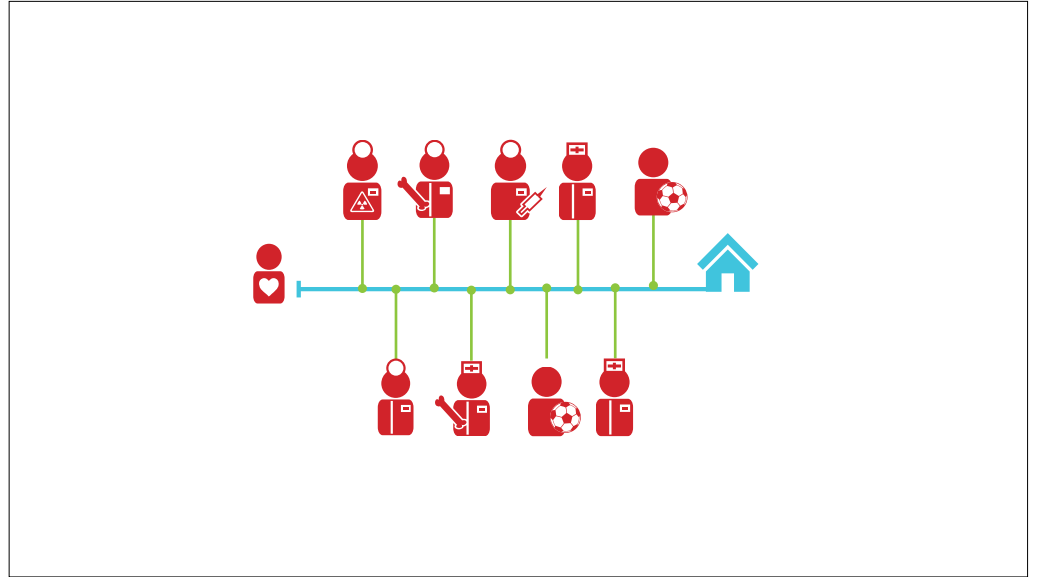
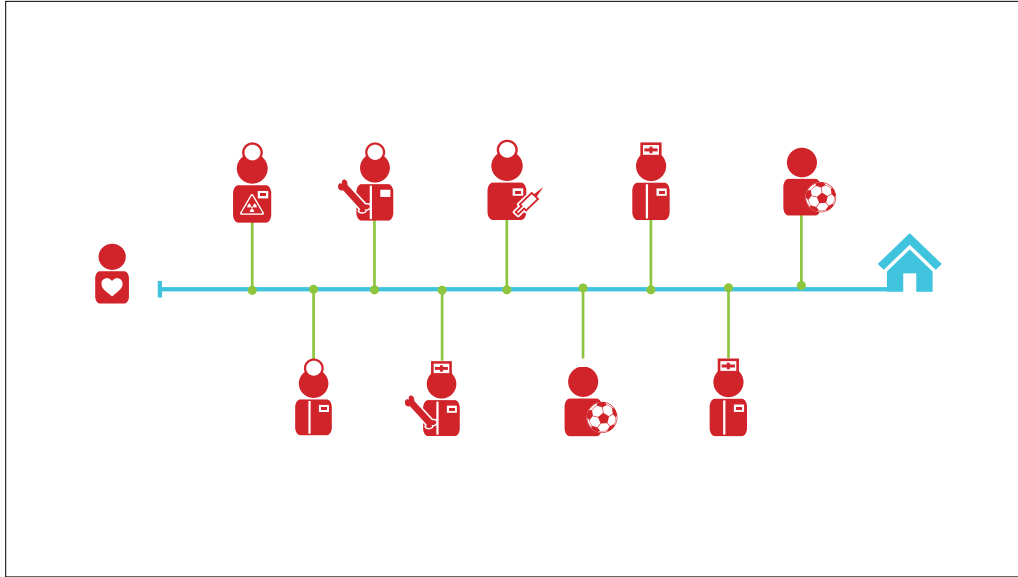
## post-operatief herstel

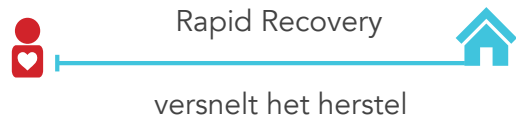

Henrik Kehlet, British Journal of Anaesthesia 1997;78:606-617

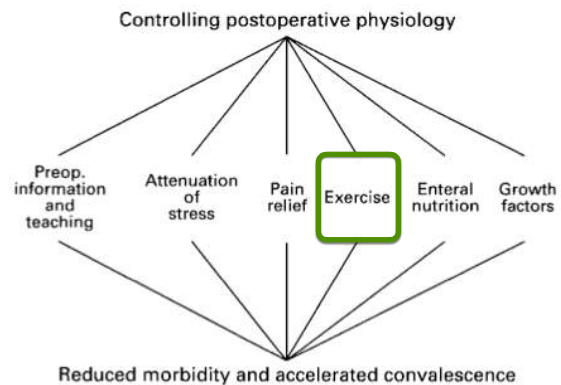
## snel herstel







## post-operatief herstel



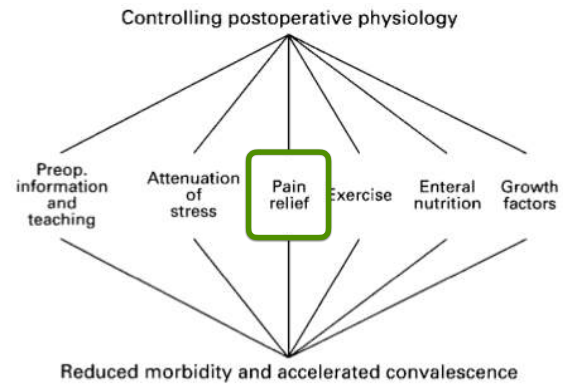
Henrik Kehlet, British Journal of Anaesthesia 1997;78:606-617

## post-operatief herstel



zo snel mogelijk mobiliseren

## post-operatief herstel



Henrik Kehlet, British Journal of Anaesthesia 1997;78:606-617

## post-operatief herstel

**pre medication 2 h pre operatively**  
400 mg Celecoxib  
1 gram Paracetamol

**after surgery**  
4 h: 1 gram Paracetamol  
8 h: 1 gram Paracetamol and 300 mg Gabapentin  
First postoperative night: Oxycodon 10 mg

**day 1**  
4x 1 gram Paracetamol  
200 mg Celecoxib (morning)

**day 2**  
200 mg Celecoxib (14 days post surgery)  
4x 1 gram Paracetamol

**rescue medication**  
200 mg Celecoxib extra from day 1

**pre-operative**  
dexamethason 0.15 mg/kg in 50 cc NaCl in 10 minutes

antibiotic prophylaxis, cefazolin 2 gr

**spinal**  
low dose Bupivacaine 6 mg, no opiate

**per-operatively**  
propofol sedation, target 1 - 2

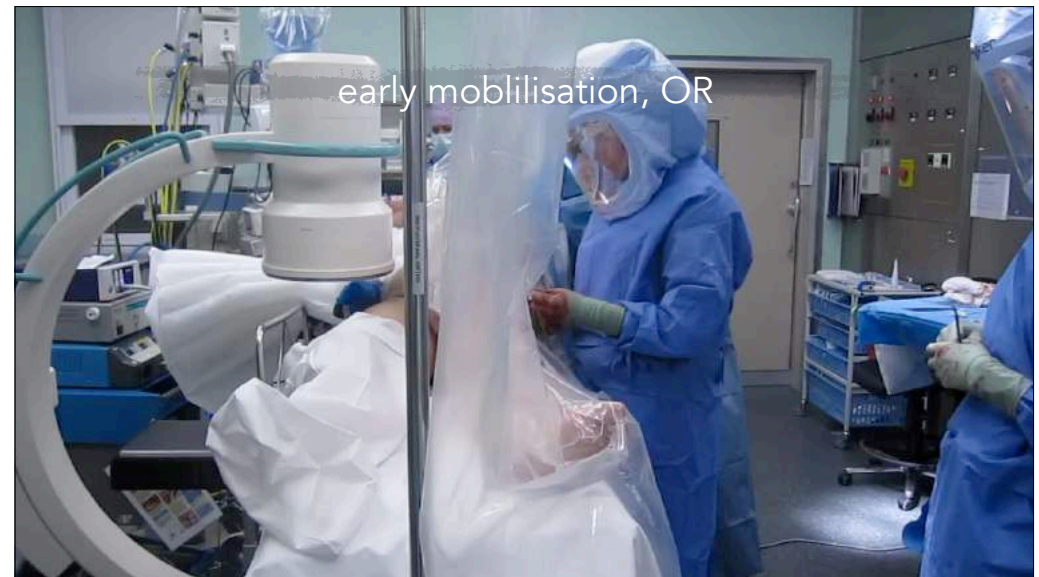single dose ketamine 15 mg

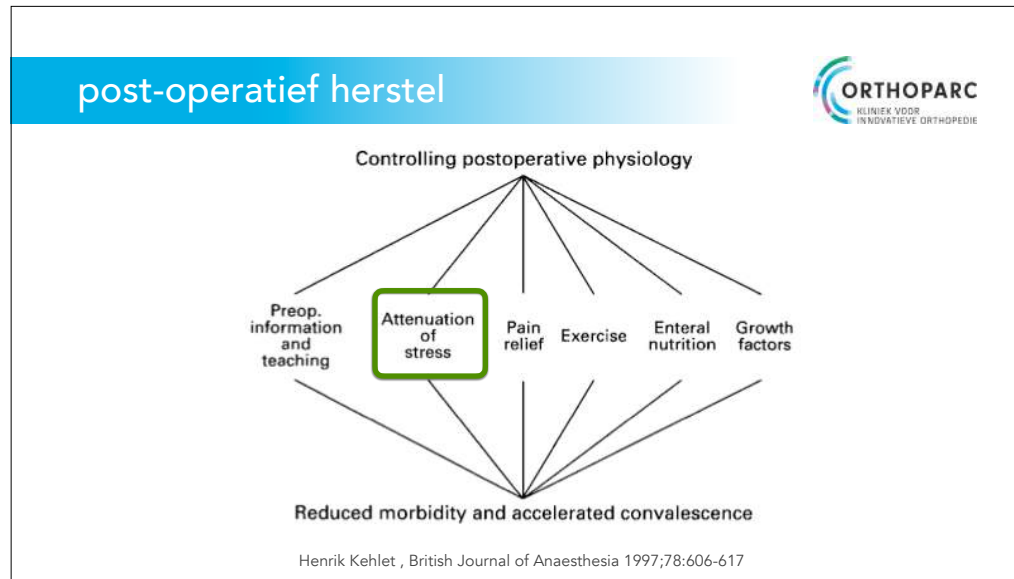
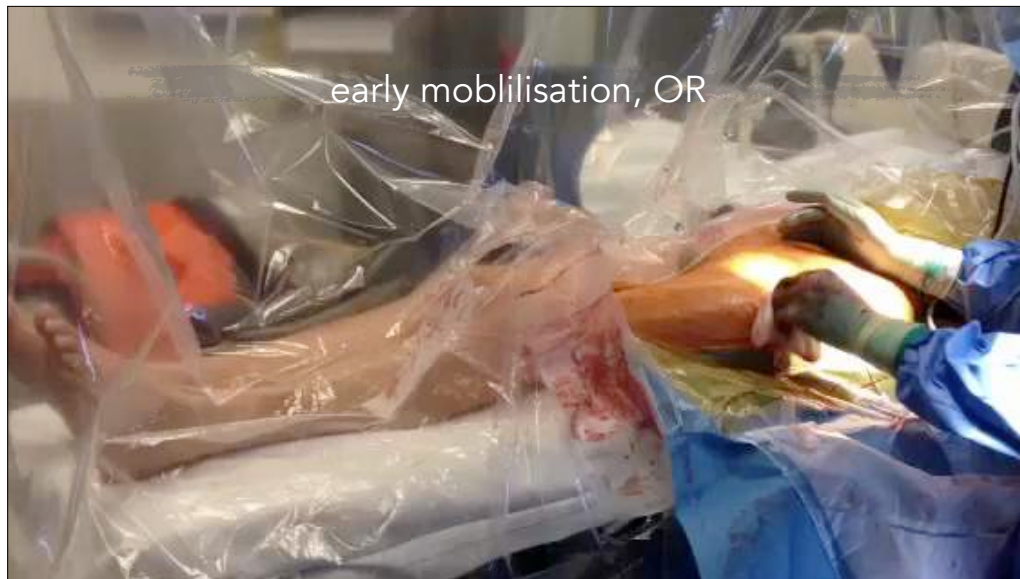cyklokapron (tranaxamic acid), preoperatively AND postoperatively  
<100kg: 1000 mg  
>100kg: 1500mg

## post-operatief herstel

vroeg mobiliseren, OK

effect van lage dosis spinaal






anterieure benadering

AMIS

direct anterior approach (DAA)

anterior supine inter muscular / inter nervous (ASI)



# GRUNDRISS DER CHIRURGIE

von  
Dr. C. HUETER,

Zweite sorgfältig durchgesehene Auflage

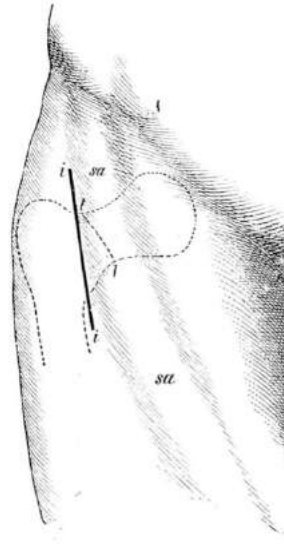
von  
Prof. Dr. HERMANN LOSSEN

II. BAND.  
SPECIELLER THEIL.

ERSTE ABTHEILUNG.  
Die chirurgischen Krankheiten des Kopfes.

MIT 108 ABBILDUNGEN.

LEIPZIG,  
VERLAG VON F. C. W. VOGEL  
1882.

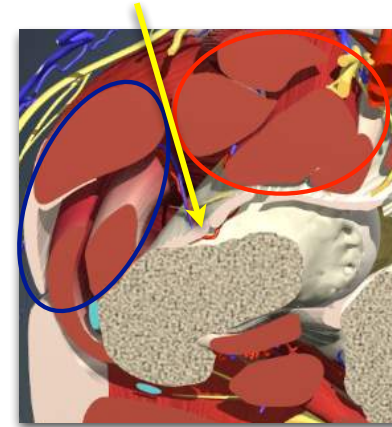


## inter musculair vlak



tensor fascia lata  
gluteus medius  
gluteus minimus

n gluteus superior

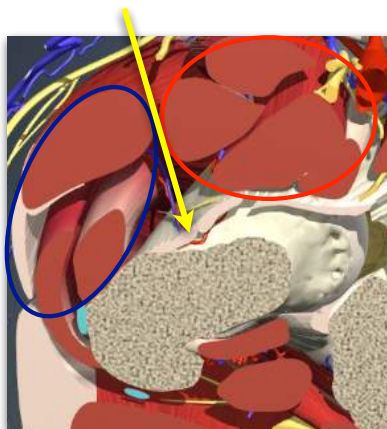


n femoralis  
sartorius  
rectus femoris  
psoas

## inter nerveus vlak

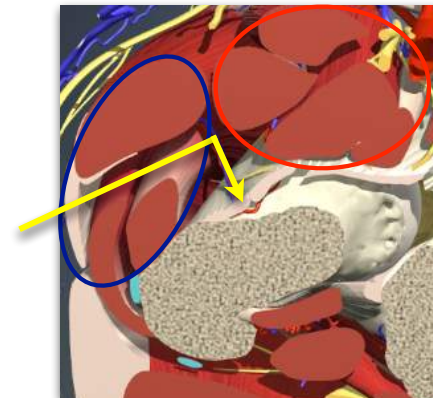


tensor fascia lata  
gluteus medius  
gluteus minimus  
n gluteus superior



n femoralis  
sartorius  
rectus femoris  
psoas

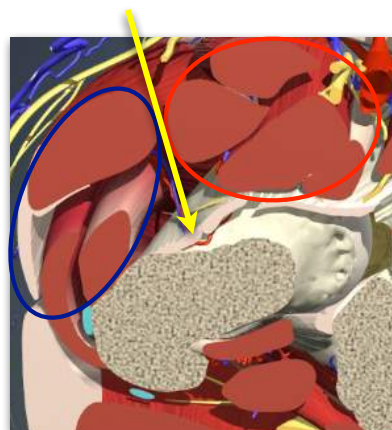
## anterolaterale benadering



## ASI benadering



geen risico op  
denervatie  
atrofie  
Trendelenburg



## voordelen ASI benadering



cup plaatsing  
beenlengte correctie  
minder gebruik van krukken\*  
snel postoperatief functioneel herstel\*

\* den Hartog YM, Mathijssen NM, Vehmeijer SB. The less invasive anterior approach for total hip arthroplasty: a comparison to other approaches and an evaluation of the learning curve - a systematic review. Hip Int. 2016 Mar-Apr;26(2):105-20.

## voordelen ASI benadering



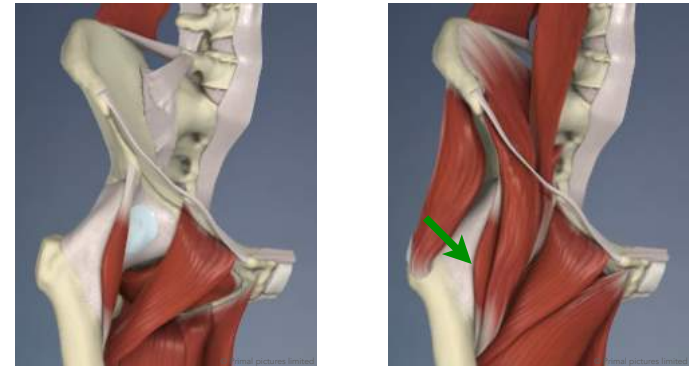
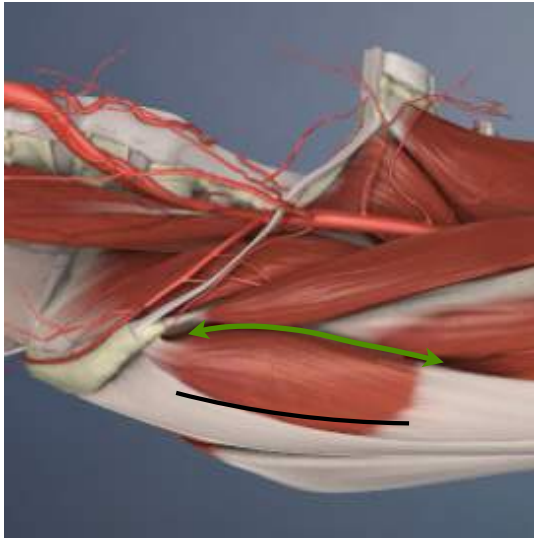
cup plaatsing  
beenlengte correctie  
minder gebruik van krukken\*  
snel postoperatief functioneel herstel\*

\* den Hartog YM, Mathijssen NM, Vehmeijer SB. The less invasive anterior approach for total hip arthroplasty: a comparison to other approaches and an evaluation of the learning curve - a systematic review. Hip Int. 2016 Mar-Apr;26(2):105-20.

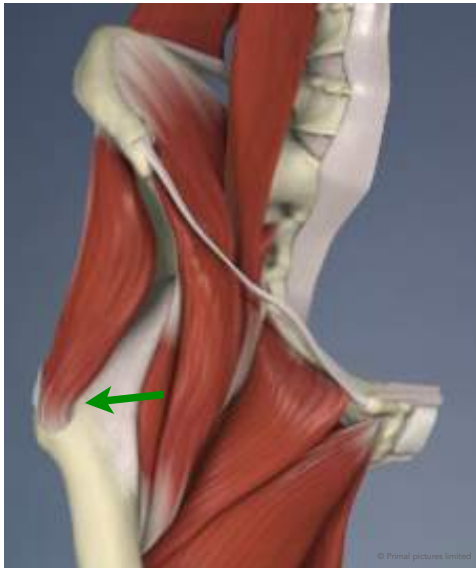## techniek ASI benadering



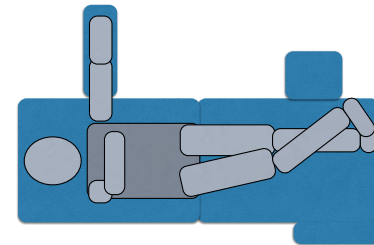


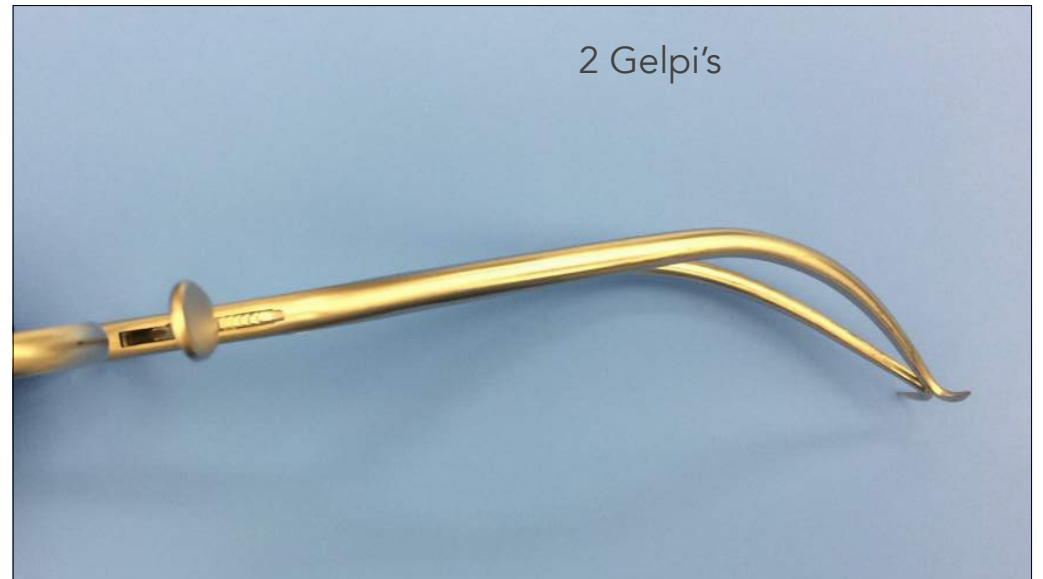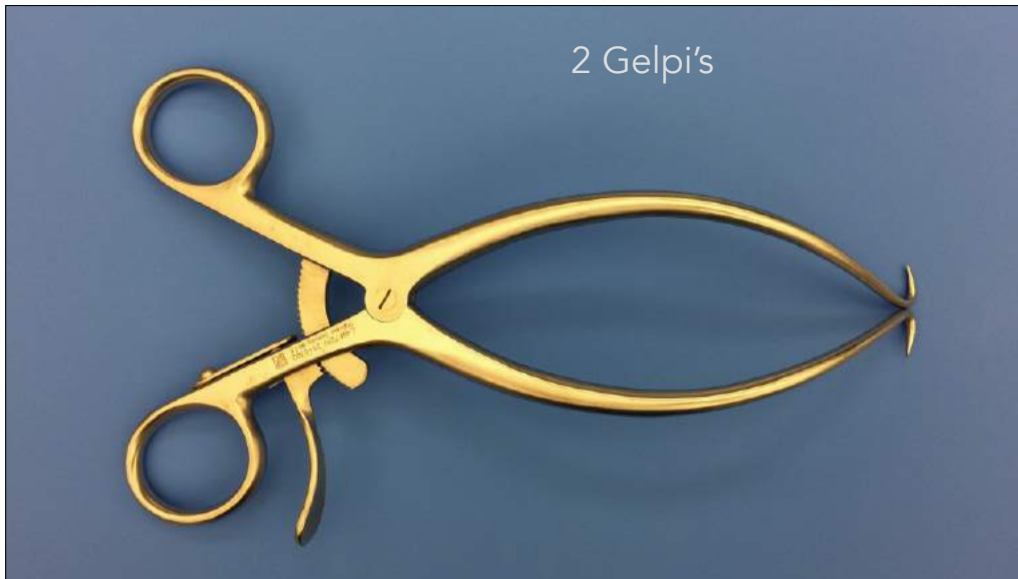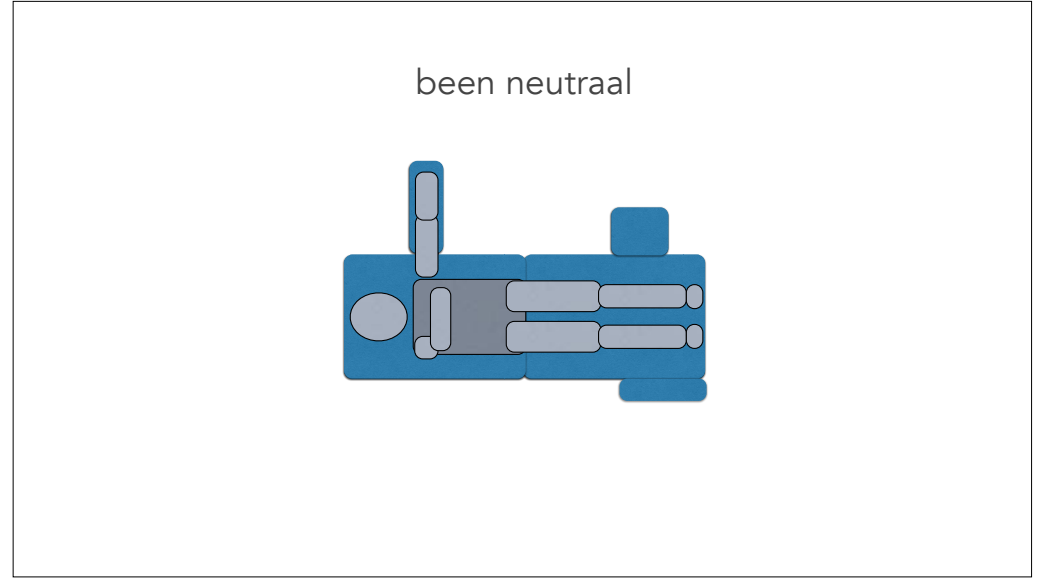


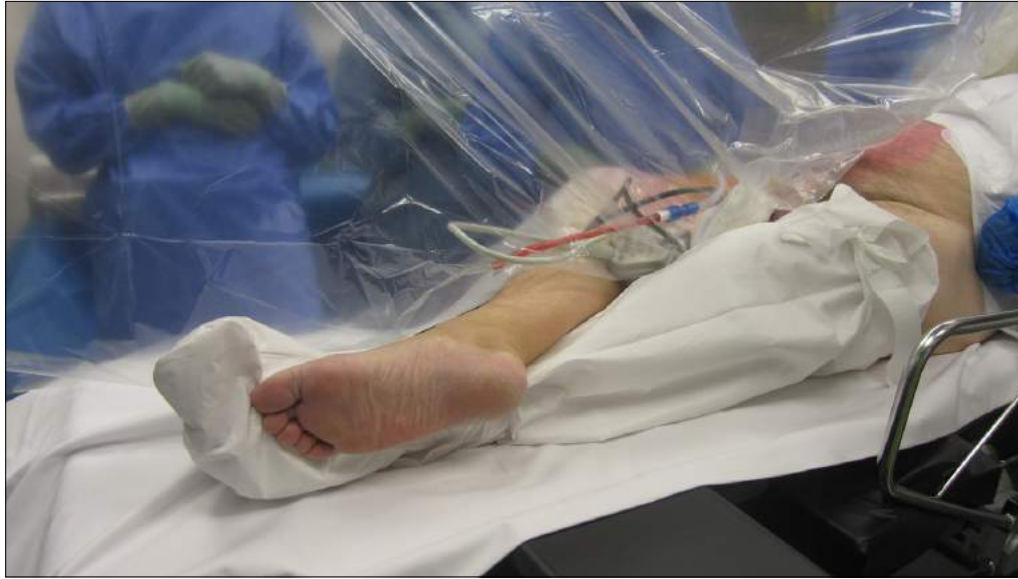m iliocapsularis



been over het andere been





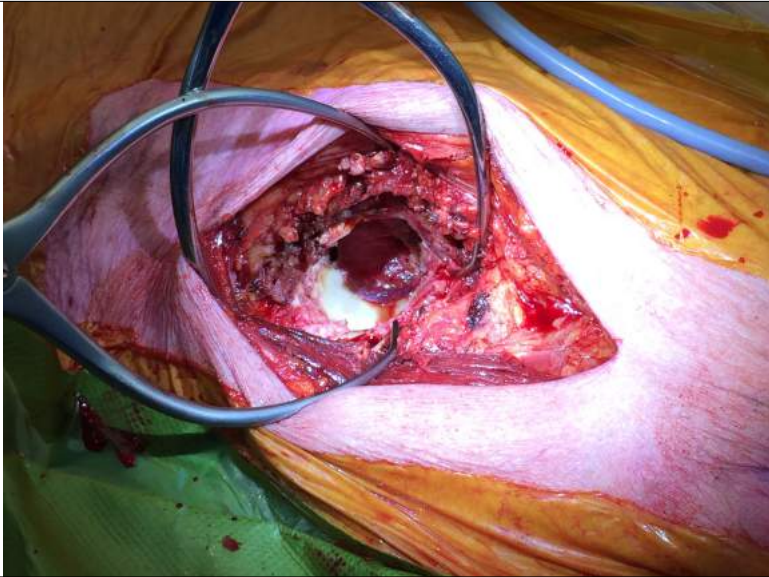
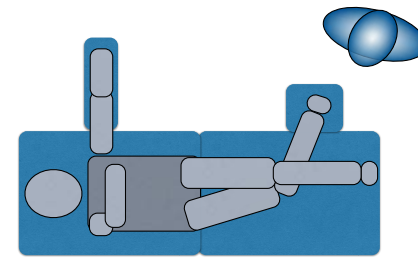
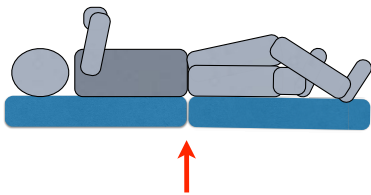


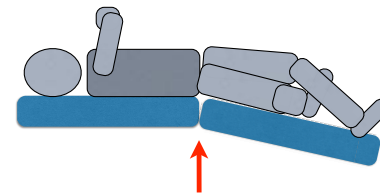
figure of four

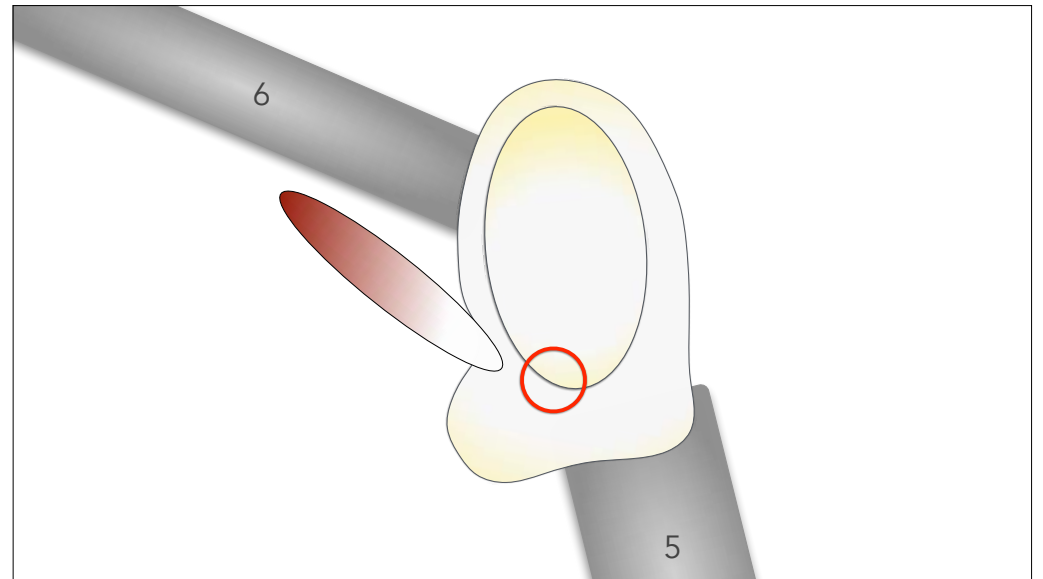
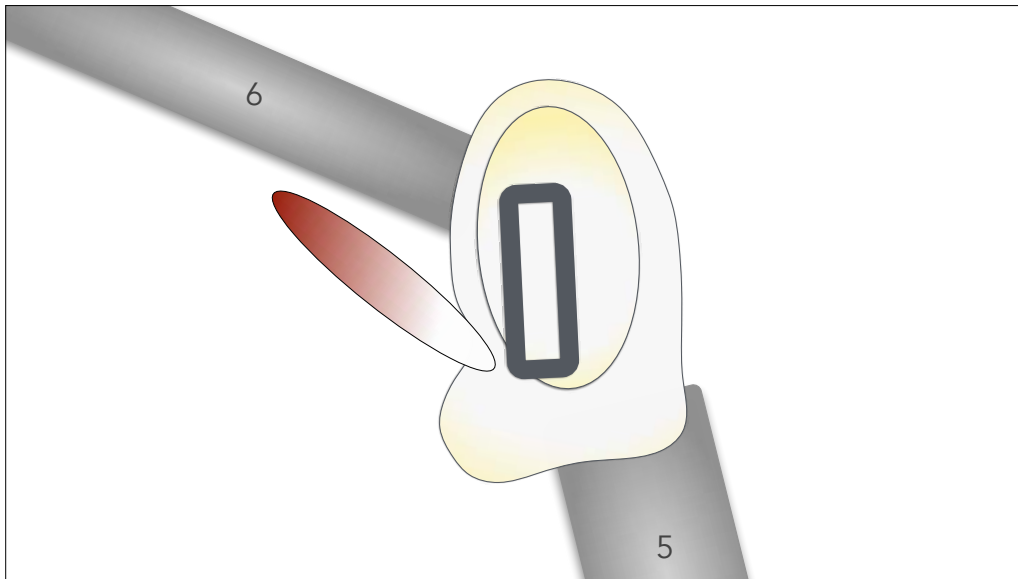
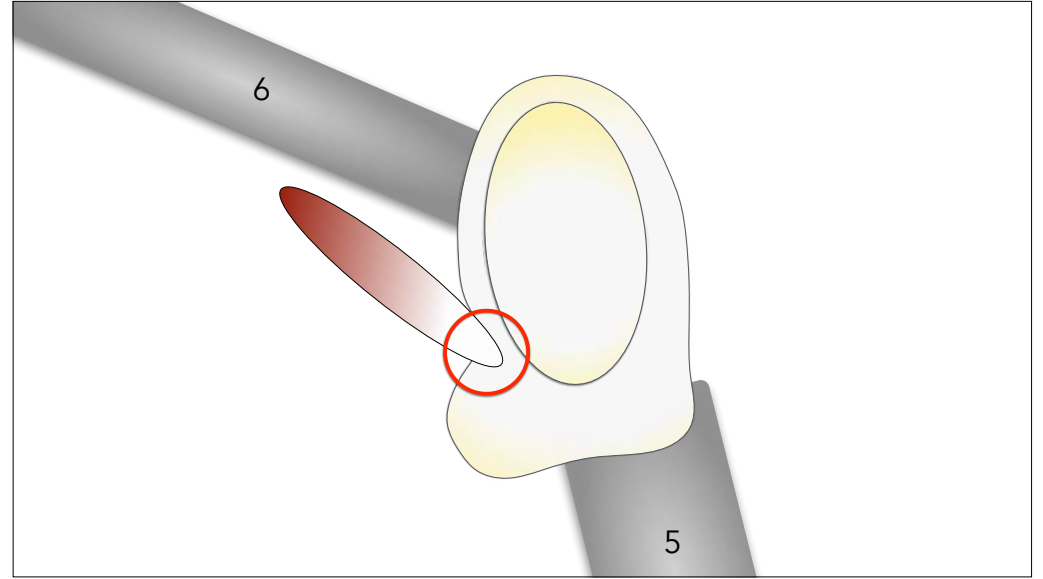
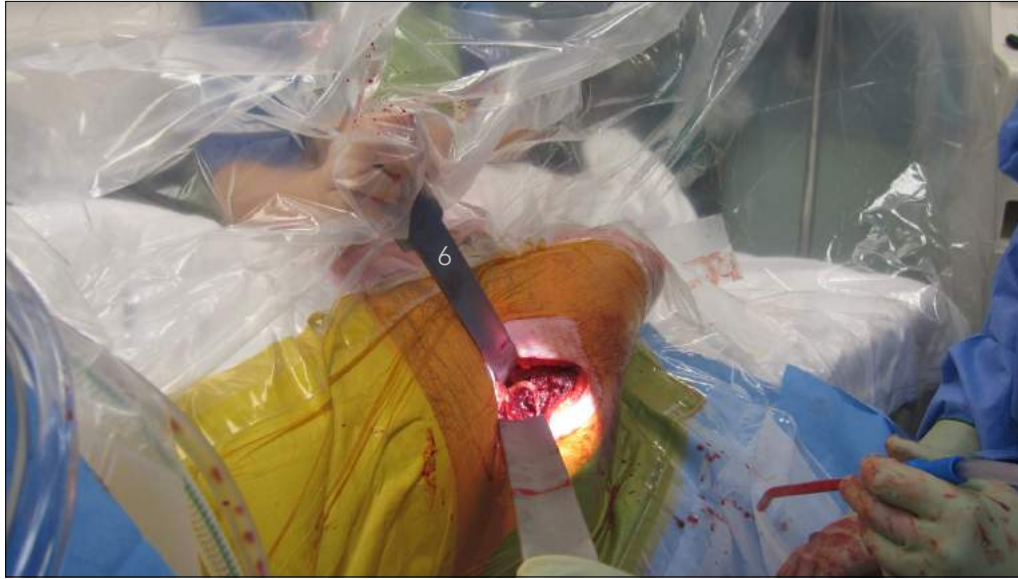

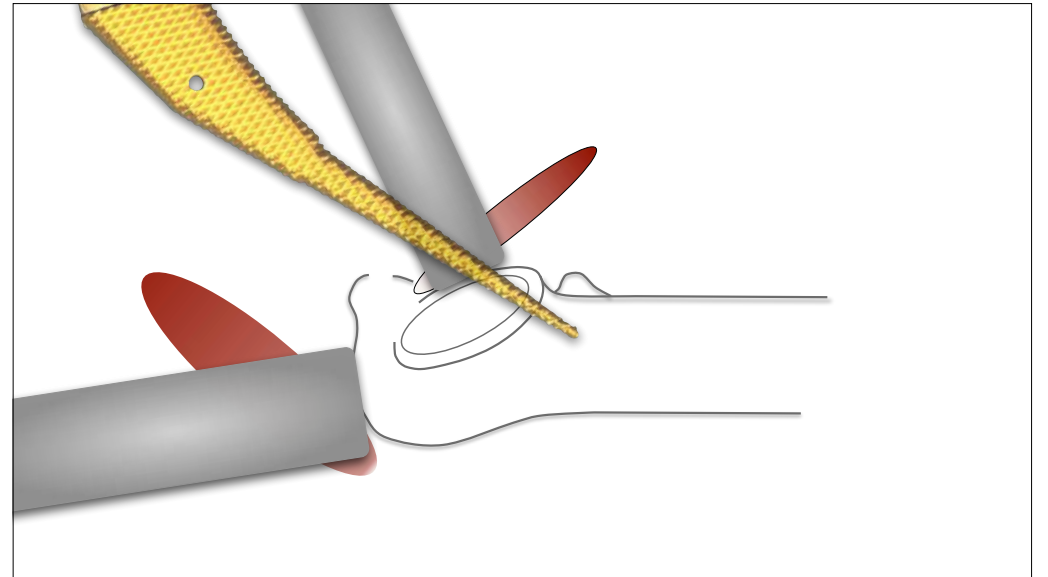
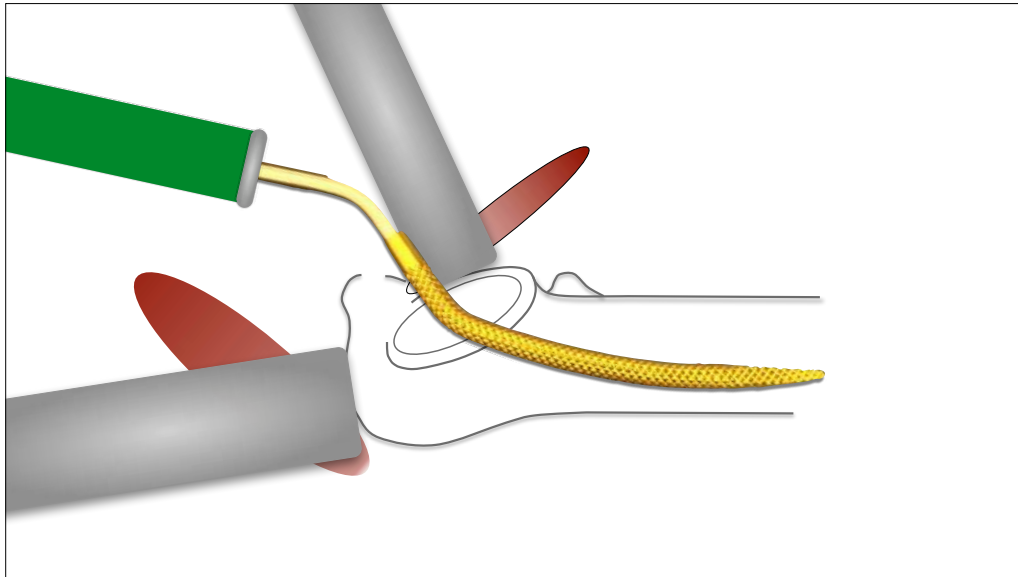
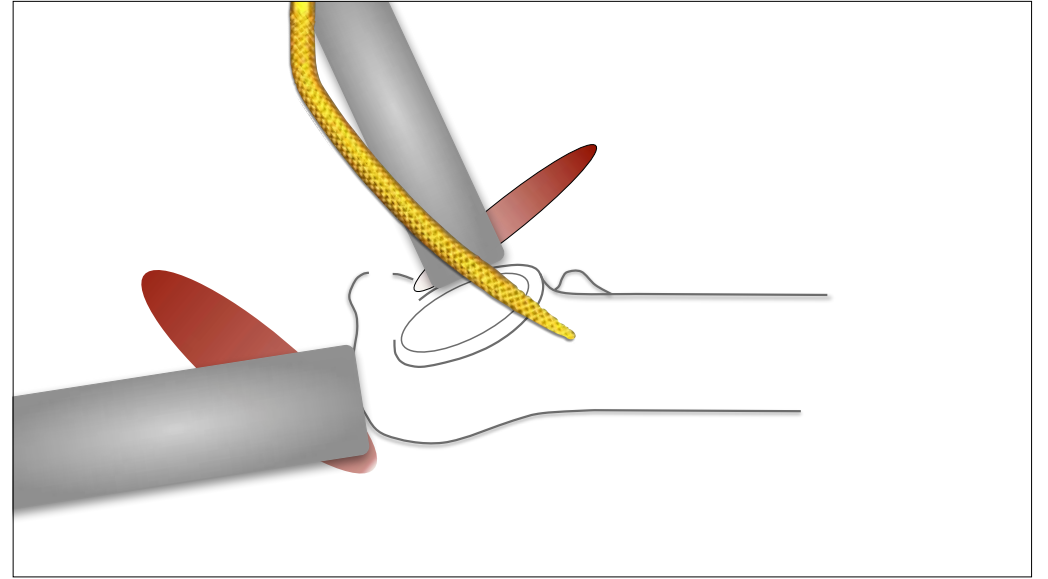
tafel 30° knikken

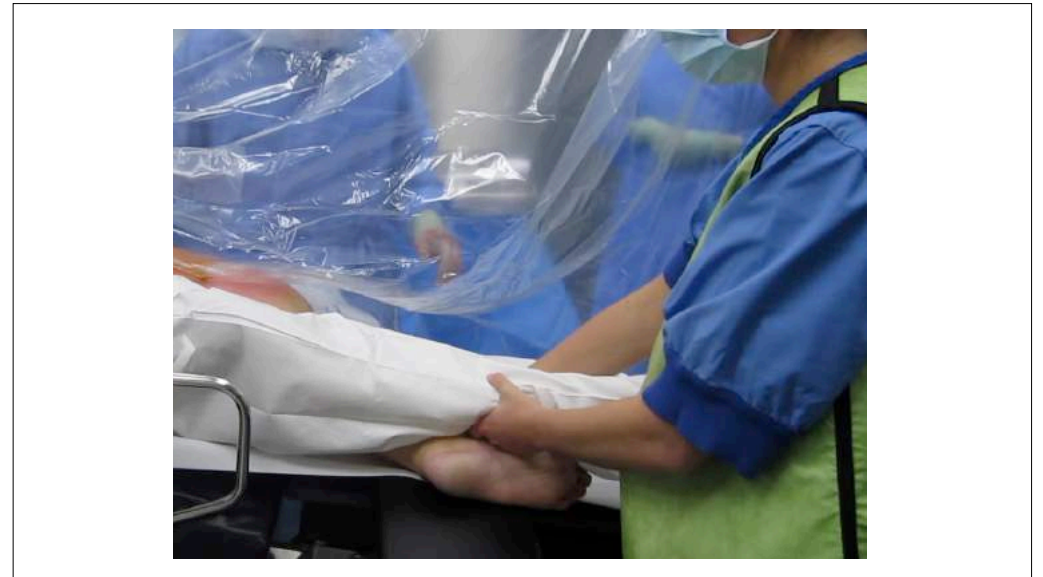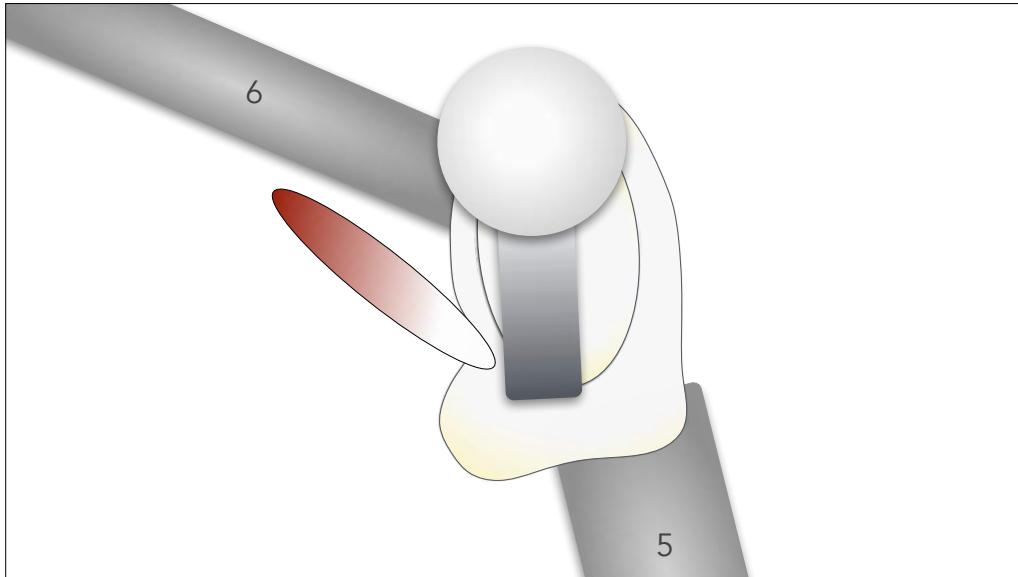
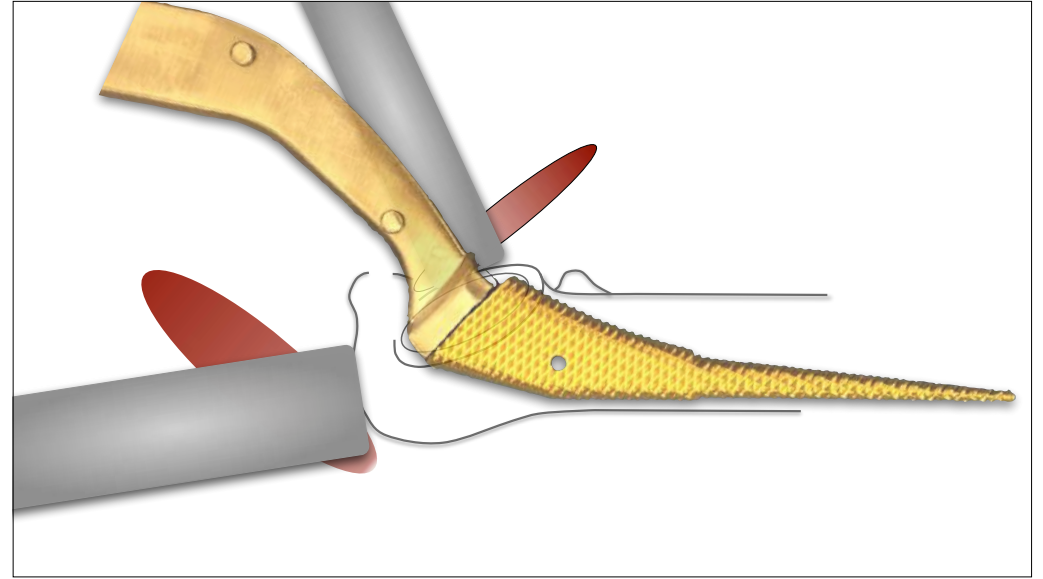
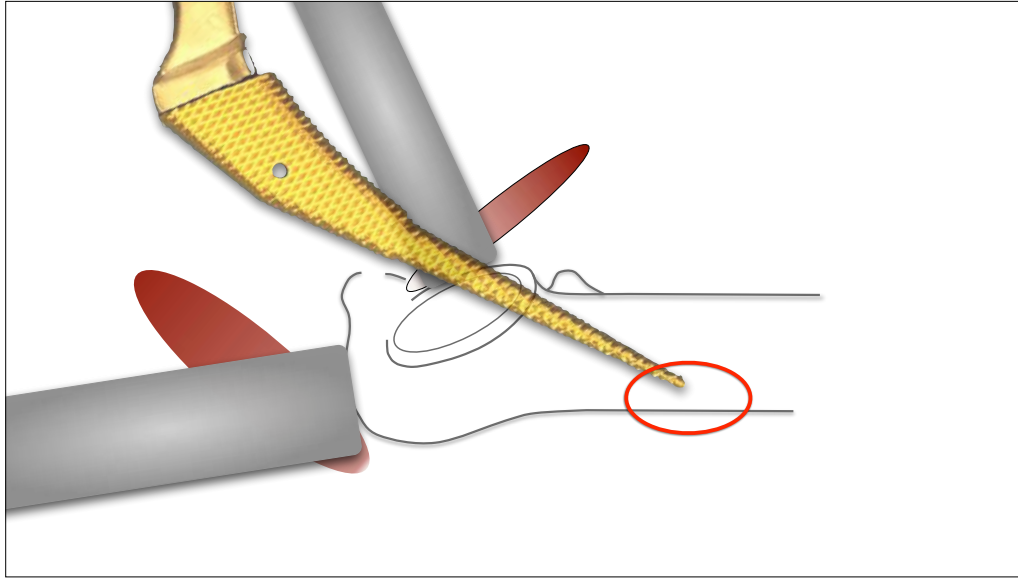


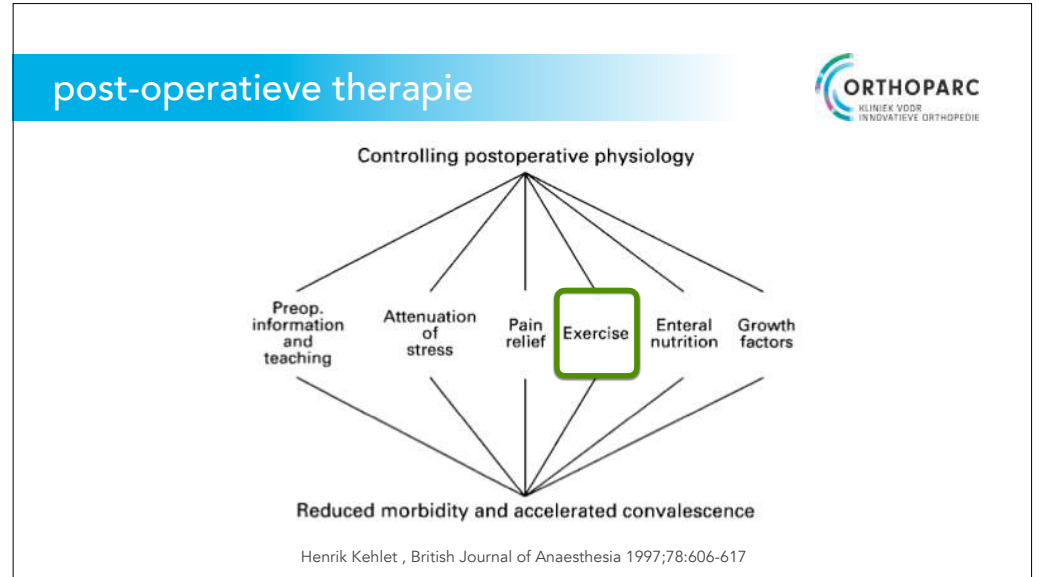
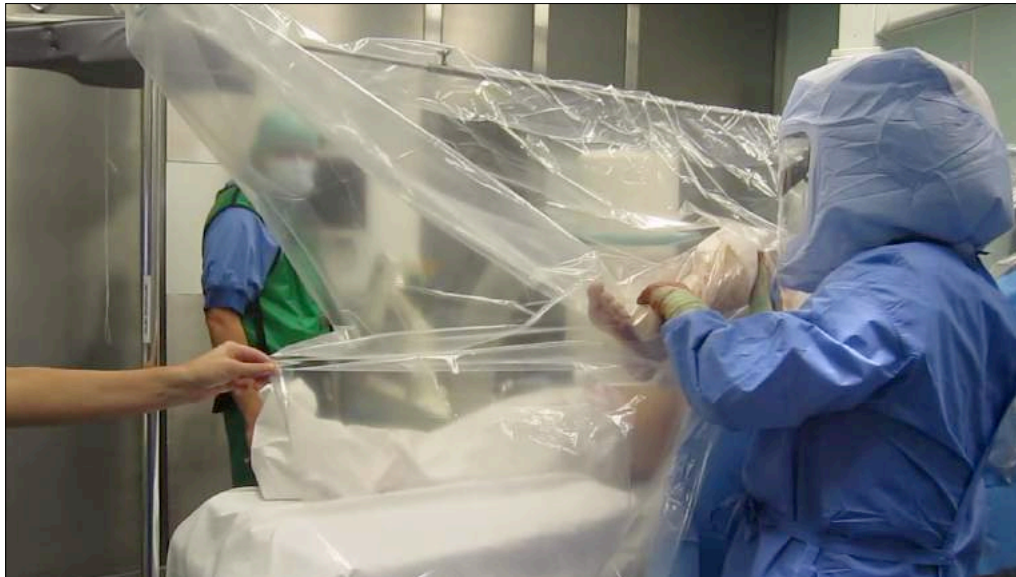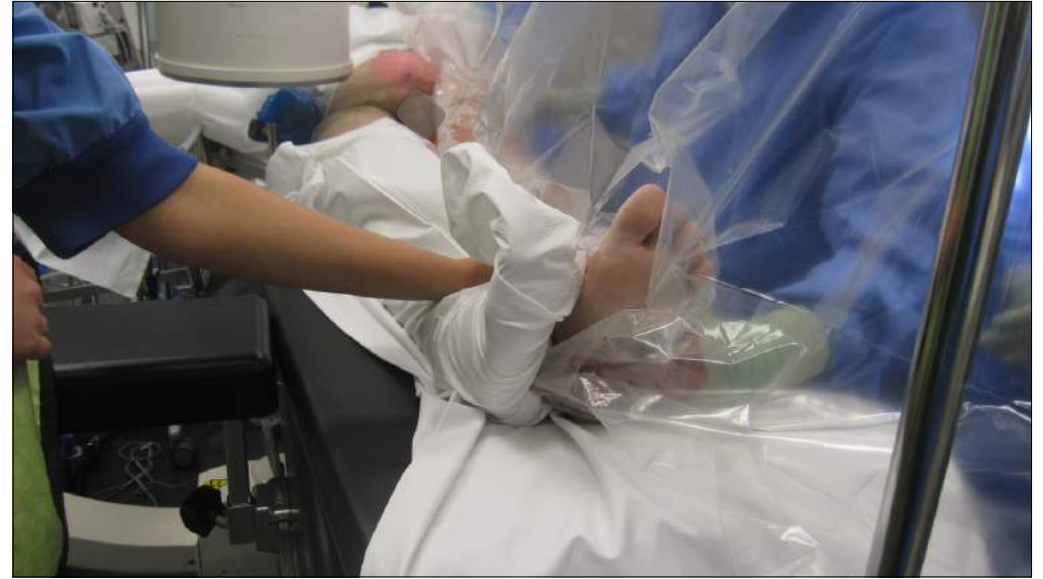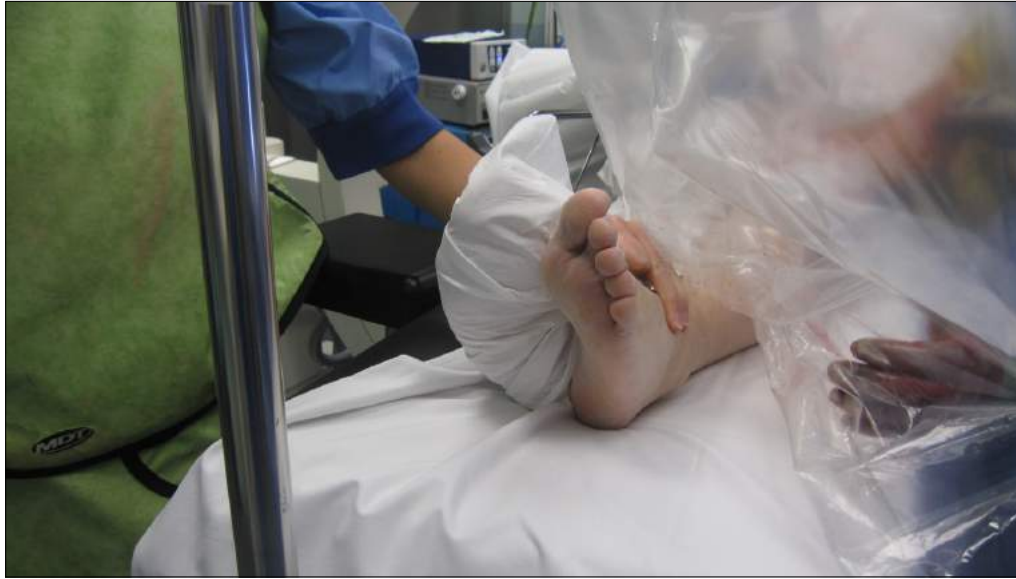tafel 30° knikken











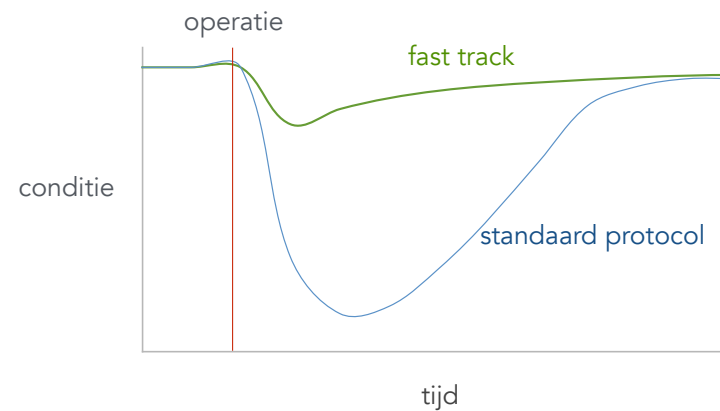
## post-operatief herstel



gras groeit niet harder door er aan te trekken



## snel herstel



## post-operatief herstel



therapeut heeft een coachende rol

## post-operatief herstel



nadruk op functioneel herstel  
en herstel van het looppatroon



## post-operatief herstel



eerste 6 weken  
geen kracht- of stabiliteitsoefeningen

## post-operatief herstel



eerste 6 weken  
geen manipulatie of passief oefenen

## post-operatief herstel



na 6 weken  
gericht op verwachtingen en wensen van de  
patiënt

## dank voor jullie aandacht



[s.vehmeijer@orthoparc.nl](mailto:s.vehmeijer@orthoparc.nl)